

First live stranding of a leatherback sea turtle *Dermochelys coriacea* in Alagoas, north-east Brazil

WALTYANE A.G. BONFIM^{1*}, BRUNO STEFANIS S.P. DE OLIVEIRA^{1,4}, CAIO RODRIGO MOURA SANTOS¹, LUCIANA SANTOS MEDEIROS^{1,2} & MARÍA FERNANDA DE LA FUENTE^{1,3}

¹Instituto Biota de Conservação, Maceió, 57038-770, Brazil

²Postgraduate Programme in Animal Science, Federal University of Alagoas, Rio Largo, 57100-000, Brazil

³Postgraduate Programme in Ethnobiology and Nature Conservation, State University of Paraíba, Campina Grande, 58429-500, Brazil

⁴Postgraduate Programme in Biological Sciences, Federal University of Paraíba, João Pessoa, 58051-900, Brazil

*Corresponding author e-mail: waltyanebonfim@institutobiota.org.br

Since 2009, the NGO Biota (Instituto Biota de Conservação) has developed several activities focused on the management, research and conservation of marine animals along the coast of Alagoas (Brazil). This has included a periodic beach monitoring programme to record sea turtle egg laying, hatchling emergence, and stranded marine animals (turtles, mammals and birds). In addition, Biota involves local communities in this monitoring where they can participate by sending records and information of stranded animals (including photos for species identification and animal state, GPS of locations, date and hour, etc.).

The leatherback sea turtle *Dermochelys coriacea* (Vandelli, 1761) (Testudines: Dermochelyidae) is a pelagic species with a circumglobal distribution, with feeding areas in temperate and subarctic zones and breeding areas in tropical zones (Eckert et al., 2012). Its distribution in Brazil is discontinuous, with scattered records from the north-east, south-east and south of the country (Barata et al., 2004). The species is categorised as Vulnerable in the IUCN's Red List of Threatened Species (Wallace et al., 2013) and Critically Endangered in the Brazilian List of Fauna Threatened with Extinction (BRASIL, 2014).

In Brazil, several factors put the leatherback under particular conservation threat: the low estimated number of females breeding in each reproductive season (between 1 and 18) in a restricted geographical range for nesting (Espírito Santo); the apparent isolation of the population (high philopatry) (Thomé et al., 2007, Colman et al., 2019) and exposure to pollution, coastal development, climate change and especially industrial fishing activities (Colman et al., 2019; Sales et al., 2008). In this context, every individual is important for the recovery and maintenance of the regional population. Here, we describe the first recorded stranding of *D. coriacea* in the state of Alagoas (north-east of Brazil) including information about its rescue, management and release.

At 19:00 h on 22 April 2013, fishermen made a report to Biota of a female leatherback sea turtle found alive on the beach Lagoa do Pau in Coruripe, Alagoas (10.106247° S, 36.098132° W) (Fig. 1). The Biota team promptly activated its protocol for attending a stranding and the rescue team arrived at 19:20 h. The female turtle had a curved carapace length of 146 cm and curved carapace width of 107 cm, suggesting that the turtle was of reproductive age (Zug & Parham, 1996; Avens

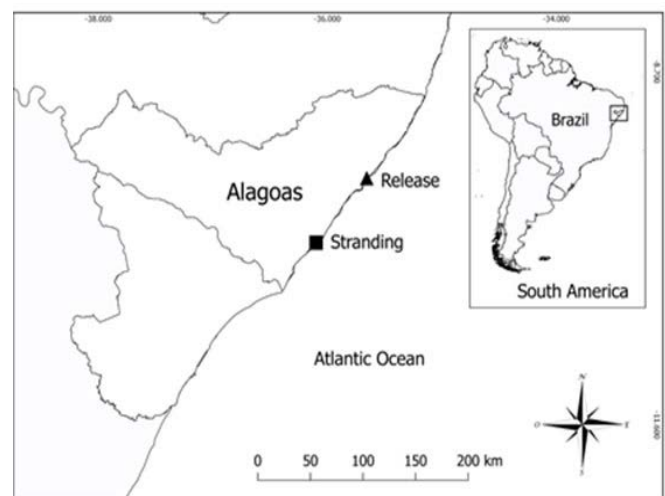


Figure 1. Map of the state of Alagoas, Brazil, indicating the stranding and release sites of the female leatherback turtle

et al., 2009). With the help of fishermen and local residents several attempts were made to return the animal to the ocean, but every time the waves brought it back to shore. The turtle was lethargic and prostrate and, after confirming that it was not able to return to the sea by itself, a decision was made to intervene. At 21:30 h, six adult men carried her (~20 m), with the help of a tarpaulin placed under the plastron, to a pickup truck (Chevrolet S10) in which it was transported to the rehabilitation facility. The turtle was placed at the back of the pickup truck and the careful transport took ~2:25 hours (92 km). During transportation and subsequent treatment, the animal was constantly monitored and watered to prevent drying of the carapace and ocular region.

At the rehabilitation facility, the leatherback was carried by eight adult men and accommodated in a partially filled 2000 litre pool (Fig. 2a); a lower water level was used to facilitate breathing and lubrication of the eyes. Following a clinical evaluation conducted at the pool and a visual-assessment of its body condition (plastron shape and tissue bulk around the neck and shoulders, Thomson et al., 2009), the animal was found to have a good nutritional status. Nonetheless, it had multifocal erosive lesions with caseous deposits on the




Figure 2. Adult female leatherback turtle with anterior right flipper amputated - **A.** In rehabilitation after the rescue, and **B.** During release back into the sea

carapace and plastron. Moreover, the anterior right flipper had been amputated and was healed. Since only a shallow pool was used for examination, it was not possible to assess the specimen's buoyancy. The animal received subcutaneous fluid therapy (15 ml/kg/day, Ringer's lactate, glucose 5 %, sodium chloride 0.9 %, multivitamin), antibiotic therapy (Enrofloxacin 5 mg/kg), liver protector using the allometric extrapolation method (Pachaly, 2007; 0.01 ml/kg, anti-toxic multi vitamin and multi aminoacid: acetylmethionine, choline (chloride), riboflavin (phosphate), pyridoxine (hydrochloride), nicotinamide, dextrose) and cleaning/treatment for the carapace lesions (debridement, povidone iodine and antibacterial ointment). These clinical procedures were performed every 48 h during the rehabilitation period, respecting the recommended dosage interval of the antibiotic (Carpenter, 2005) and to reduce animal handling and stress. It was not possible to conduct additional tests due to the lack of appropriate equipment for collecting blood from an animal of this size and the impracticality of radiographic examination.

Although various fresh cnidaria (jellyfish and caravels) were offered, we did not observe the turtle spontaneously feeding. To avoid stress and potential weakening of the animal, a decision was made to release it back into the sea as soon as possible. It was released at 12:12 h on Riacho Doce beach, Alagoas (9.576012 S, 35.655377 W) (Fig. 1), five days after the stranding and shortly after receiving another dose of fluid and antibiotic therapy. The animal was placed on a raft that was transported beyond the wave zone and there released (Fig. 2b). It was observed to float for a few minutes, drifting close to a sandstone reef; after approximately one hour, visual contact was lost. The night of the release and on the following mornings the Biota team monitored the adjacent beaches in case of a repeated stranding. Furthermore, partners around the state were alerted in case of a possible stranding. The animal was not sighted again.

In Brazil, the main leatherback sea turtle breeding area (of the south-west Atlantic Ocean subpopulation) is located in the southern state of Espírito Santo (Thomé et al., 2007), ~1,100 km, in a straight line, from the stranding site here described. However, other occasional breeding sites have been recorded in the north-east (Prado, southern state of Bahia: Barata & Fabiano, 2002; Luís Correia, state of Piauí: Loebmann et al., 2008; Cajueiro da Praia, Luís Correia and Parnaíba, state of Piauí: Silva et al., 2010; Entre Rios, northern state of Bahia: Gandu et al., 2014). Typically, the nesting season for this species occurs between October and February (Thomé et al., 2007). These highly migratory animals move great distances between nesting and foraging sites (Almeida et al., 2011) and *D. coriacea* turtles from other subpopulations are recorded elsewhere along the Brazilian coast (Colman et al., 2019). Since the stranded individual did not have an identification tag, there is insufficient information to surmise the subpopulation to which it belongs.

A compilation of sightings, strandings and incidental captures of leatherback turtles on the Brazilian coast from 1969 to 2001 (Barata et al., 2004) indicates that the majority of these events involved either dead animals that were washed up or incidental captures in fishing tackle. Live *D. coriacea* stranding records in Brazil are rare; only one previous live stranding had been recorded on the north-east coast, near Salvador, Bahia in February 1999 (Barata et al., 2004). The right flipper of the female of the present report had been amputated by an unknown cause, however the lesion's characteristics were similar to those reported for specimens of *Caretta* that had been caught in plastic/nylon cords of fishing nets (Barreiros & Raykov, 2014). The absence of the right flipper is unlikely to be the cause of the stranding but it may have had some influence given the turtle's size and weight. The absence of the flipper could have resulted in some difficulty swimming, diving or even in movements to avoid accidents (i.e., collisions and fishing nets). Moreover, the extra effort of swimming with only three flippers can result in an increase in energy expenditure (Franchini et al., 2020).

Although there is some information about health parameters of free-living leatherbacks (e.g. Innis et al., 2010), there is no established and standardised protocol for maintaining leatherbacks in captivity, especially for adult individuals. For this reason, a decision was made to return

the stranded individual to the sea quickly. It is hoped that this description of a stranding event and the procedures applied (management and veterinary care) will contribute to the improvement of care in any future incidents of this kind.

ACKNOWLEDGEMENTS

The authors thank the volunteers of Instituto Biota de Conservação for assisting in the rescue, management and release of the sea turtle. The authors are also very grateful to the Instituto do Meio Ambiente de Alagoas (IMA-AL) and Batalhão de Polícia Ambiental (BPA-AL) for the logistical assistance and to the Projeto Tamar (TAMAR), Fundação Mamíferos Aquáticos (FMA) and Instituto Amigos da Natureza (INAN) for their support. We also would like to thank the fisherman that helped in the sea turtle reintroduction to the sea. This research is authorised by SISBIO/ICMBio (license No. 28187-3).

REFERENCES

- Almeida, A.P., Eckert, S.A., Bruno, S.C., Scalfoni, J.T., Giffoni, B., López-Mendilaharsu, M. & Thomé, J.C.A. (2011). Satellite-tracked movements of female *Dermochelys coriacea* from southeastern Brazil. *Endangered Species Research* 15(1): 77–86.
- Avens, L., Taylor, J.C., Goshe, L.R., Jones, T.T. & Hastings, M. (2009). Use of skeletochronological analysis to estimate the age of leatherback sea turtles *Dermochelys coriacea* in the western north Atlantic. *Endangered Species Research* 8(3): 165–77.
- Barata, P.C.R. & Fabiano, F.F. (2002). Evidence for leatherback sea turtle (*Dermochelys coriacea*) nesting in Arraial do Cabo, State of Rio de Janeiro, and a review of occasional leatherback nests in Brazil. *Marine Turtle Newsletter* 96: 13–16.
- Barata, P.C.R., Lima, E.H.S.M., Borges-Martins, M., Scalfoni, J.T., Bellini, C. & Siciliano, S. (2004). Records of the leatherback sea turtle (*Dermochelys coriacea*) on the Brazilian coast, 1969–2001. *Journal of the Marine Biological Association of the United Kingdom* 84(6): 1233–40.
- Barreiros, J.P. & Raykov, V.S. (2014). Lethal lesions and amputation caused by plastic debris and fishing gear on the loggerhead turtle *Caretta* (Linnaeus, 1758). Three case reports from terceira island, Azores (NE Atlantic). *Marine Pollution Bulletin* 86(1–2): 518–22.
- BRASIL (2014). Portaria Nº 444, De 17 de dezembro de 2014. Brasil: *Diário Oficial da União*, nº 245.
- Carpenter, J.W. (2005). *Exotic Animal Formulary*. Saunders, London, 592 pp.
- Colman, L.P., Thomé, J.C.A., Almeida, A.P., Baptistotte, C., Barata, P.C.R., Broderick, A.C., Ribeiro, F.A., Vila-Verde, L. & Godley, B.J. (2019). Thirty years of leatherback turtle *Dermochelys coriacea* nesting in Espírito Santo, Brazil, 1988–2017: reproductive biology and conservation. *Endangered Species Research* 39: 147–158.
- Eckert, K.L., Wallace, B.P., Frazier, J.G., Eckert, S.A. & Pritchard, P.C.H. (2012). *Synopsis of the biological data on the leatherback sea turtle (Dermochelys coriacea)*. US Department of Interior, Fish and Wildlife Service, Washington DC Biological Technical Publication BTP-R4015. 158 pp.
- Franchini, D., Valastro, C., Ciccarelli, S., Ricciardi, M., Lenoci, D., Corrente, M. & Di Bello, A. (2020). Assessment of residual vascularization of the limb as a prognostic factor to avoid sea turtle flipper amputation. *Journal of Wildlife Diseases* 56(1): 145–156.
- Gandu, M.D., Goldberg, D.W., Lopez, G.G. & Tognin, F. (2014). Evidence of leatherback nesting activity in northern Bahia, Brazil. *Marine Turtle Newsletter* 141: 10–12.
- Innis, C., Merigo, C., Dodge, K., Tlusty, M., Dodge, M., Sharp, B., Myers, A., McIntosh, A., Wunn, D., Perkins, C., Herdt, T.H., Norton, T. & Lutcavage, M. (2010). Health evaluation of leatherback turtles (*Dermochelys coriacea*) in the Northwestern Atlantic during direct capture and fisheries gear disentanglement. *Chelonian Conservation and Biology* 9(2): 205–222.
- Loebmann, D., Legat, J.F., Puchnick-Legat, A., Camargo, R.C.R., Erthal, S., Severo, M. & De Góes, J.M. (2008). *Dermochelys coriacea* (leatherback sea turtle). Nesting. *Herpetological Review* 39: 81.
- Pachaly, J.R. (2007). Terapêutica por extrapolação alométrica. In *Tratado de Animais Selvagens – Medicina Veterinária*, 1215–1223 pp. Cubas, Z.S., Silva, J.C.R. & Catão-Dias, J.L. (Eds). 1st edition. São Paulo: Roca.
- Sales, G., Giffoni, B.B. & Barata, P.C.R. (2008). Incidental catch of sea turtles by the Brazilian pelagic longline fishery. *Journal of the Marine Biological Association of the United Kingdom* 88(4): 853–864.
- Silva, K.P., Santana, W.M., Nascimento, M.N.P. & Machado, R.A. (2010). Registros de comportamento reprodutivo de tartaruga de couro (*Dermochelys coriacea*) no litoral do Piauí. In *XVII Encontro de Zoologia do Nordeste: Zoologia, Evolução e Meio Ambiente*, São Raimundo Nonato, Piauí, 135–136 pp.
- Thomé, J.C., Baptistotte, C., Moreira, L.M.D.P., Scalfoni, J.T., Almeida, A.P., Rieth, D.B. & Barata, P.C.R. (2007). Nesting biology and conservation of the leatherback sea turtle (*Dermochelys coriacea*) in the State of Espírito Santo, Brazil, 1988–1989 to 2003–2004. *Chelonian Conservation and Biology* 6(1): 15–27.
- Thomson, J.A., Burkholder, D., Heithaus, M.R. & Dill, L.M. (2009). Validation of a rapid visual-assessment technique for categorizing the body condition of green turtles (*Chelonia mydas*) in the field. *Copeia* 2: 251–255.
- Wallace, B.P., Tiwari, M. & Girondont, M. (2013). *Dermochelys coriacea*. *The IUCN Red List of Threatened Species*. www.iucnredlist.org (accessed on 18/05/2021). <https://dx.doi.org/10.2305/IUCN.UK.2013-2.RLTS.T6494A43526147.en>.
- Zug, G.R. & Parham, J.F. (1996). Age and growth in leatherback turtles, *Dermochelys coriacea* (Testudines: Dermochelidae): a skeletochronological analysis. *Chelonian Conservation and Biology* 2(2): 244–49.

Accepted: 1 January 2022